

Date: 07/08/2008

Patient Name: Classified
Center Name: Classified

DOB: N/A
Date of Scan: 7/2/08

Gender: M

Images provided: Cone Beam CT images in the bone window. Axial, coronal and sagittal views.

Clinical Info:

- Please look teeth #1-6 for implant placement.

Diagnostic Objectives:

1. Implant Planned
2. Rule Out Pathology

Findings:

Maxillary sinuses: Severe mucosal thickening is noted on the floor of the left maxillary sinus. There is a mild mucosal thickening in the right maxillary sinus. The sinus floor is irregular and appears to be interrupted bilaterally.

Right TMJ:

- Condylar head: Mild flattening of the superior head is noted.
- Joint space: Slightly decreased on the posterior and superior aspects.
- Fossa: Within normal limits.

Left TMJ:

- Condylar head: Mild flattening of the superior head is noted.
- Joint space: Within normal limits.
- Fossa: Within normal limits.

Maxilla: A short, slender high density object is noted in the alveolar bone above the FPD at teeth #3 and 4. A narrow vertical low density is seen in the maxillary alveolar bone just mesial to the slender high density object. Low densities are noted at the apices of teeth #14 and 15, the lesions appear to be extending toward the maxillary sinus with superior expansion and interruption of the, thickened, floor of the sinus. There is a widened periodontal ligament space around tooth #5.

Radiographic Impression:

- There is high probability of oral-antral communication and osteomyelitis noted bilaterally in the maxillary sinuses, the sinusitis noted in the left sinus is probably of odontogenic origin.
- The high density in the maxilla above the FPD at #3 and 4 is most likely a residual root with endodontic filling material or a file tip.

- The vertical low density in the right maxilla appears to be a fracture of the alveolar bone that is open communication between the antrum and the oral cavity.
- Tooth #5 may have periodontal problems.
- The low densities at teeth #14 and 15 might be apical scars.

Recommendations:

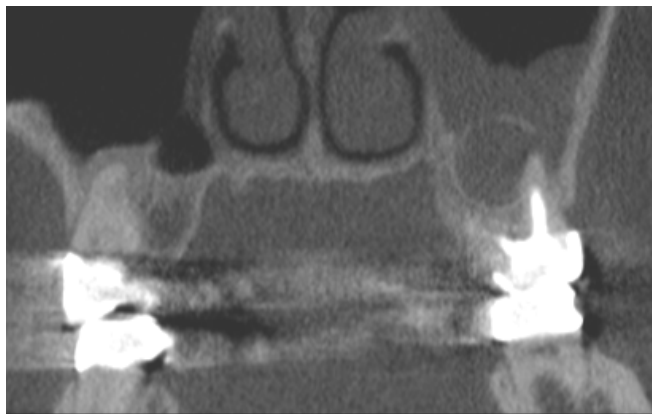
- Restorative and surgical evaluation for teeth #14 and 15 is suggested.
- Referral to ENT for sinus evaluation is suggested if dental treatment is not definitive.
- Periodontal evaluation is suggested for tooth #5.
- The measurements included in this report are to give the dentist a general idea of the amount and architecture of the remaining alveolar bone. ***Please perform your own exact measurements during treatment planning.***

Cone Beam CT images are suboptimal for the visualization of soft tissue and fine bone detail.

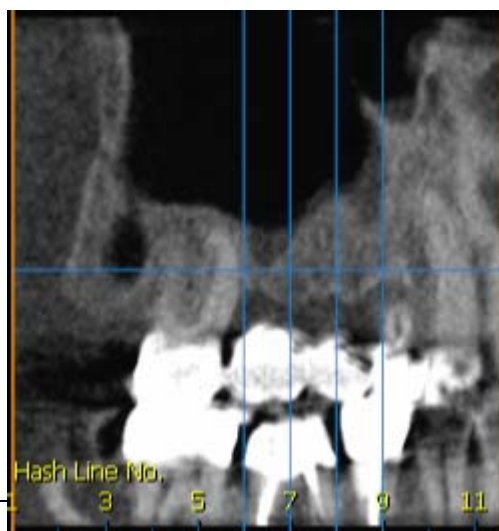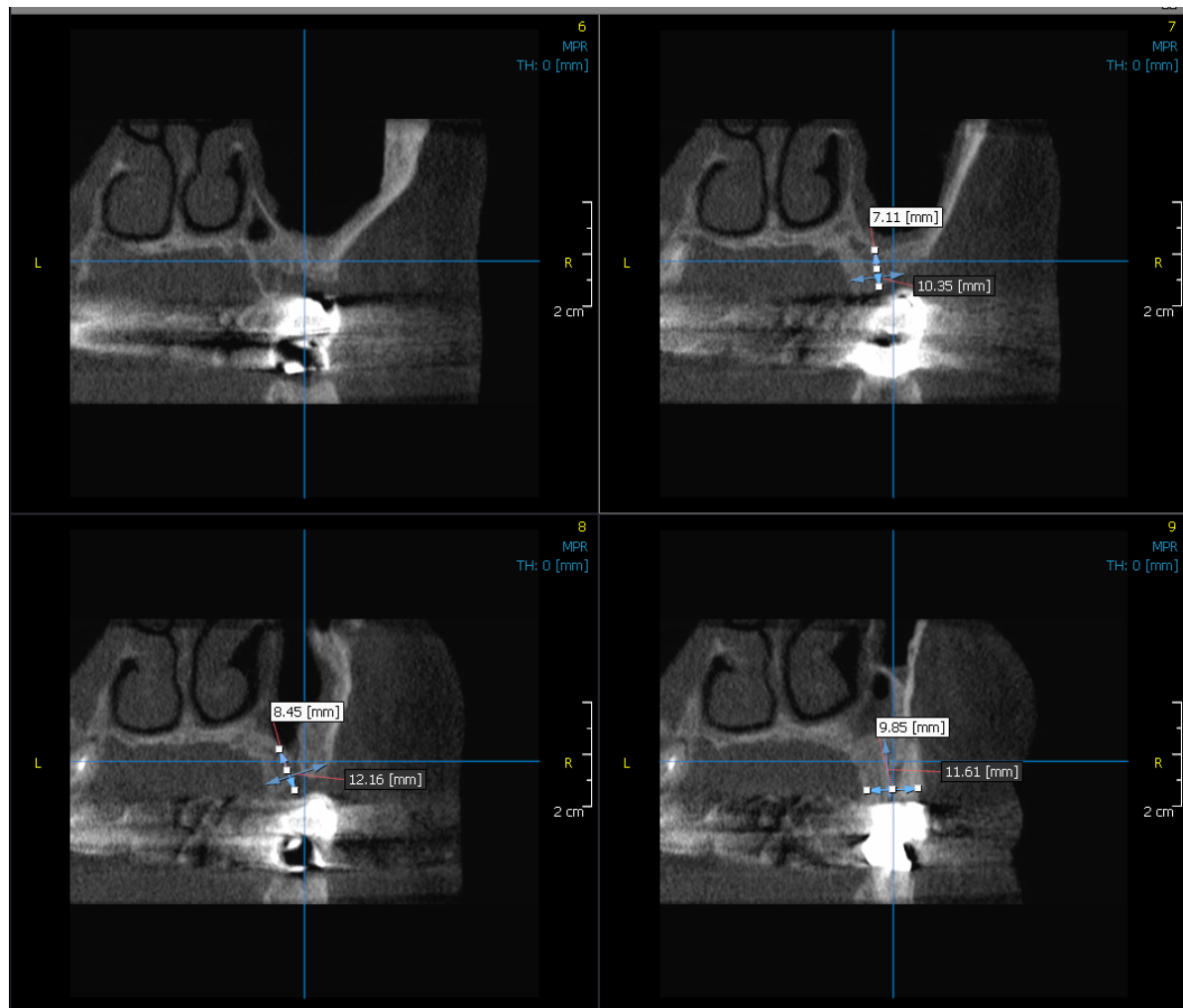
Thank you for the referral of this patient and the opportunity to serve your practice.

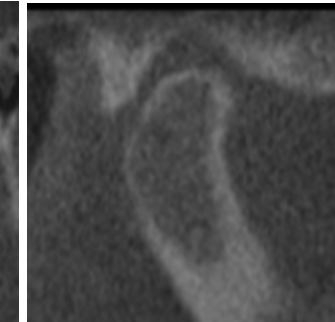
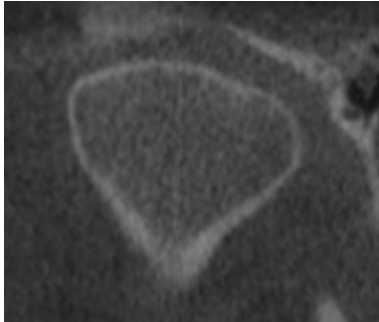


John W. Preece DDS, MS
Diplomate, American Board of Oral and Maxillofacial Radiology

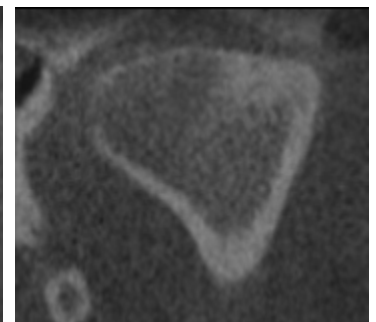
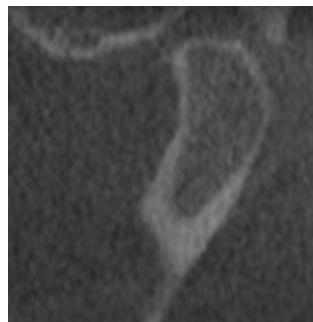


Mucosal thickening in the maxillary sinuses

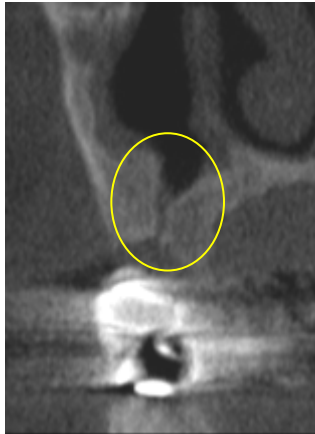




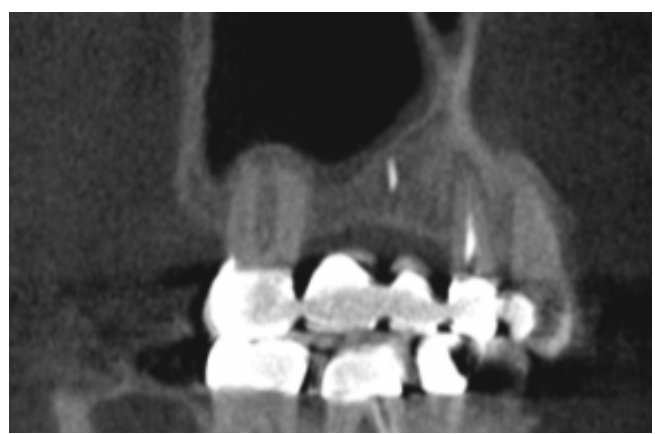
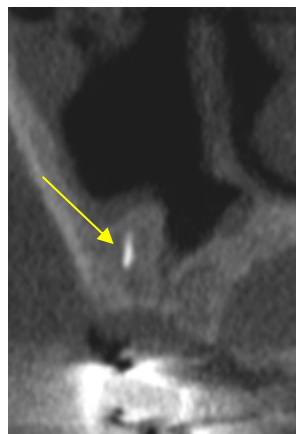Right TMJ



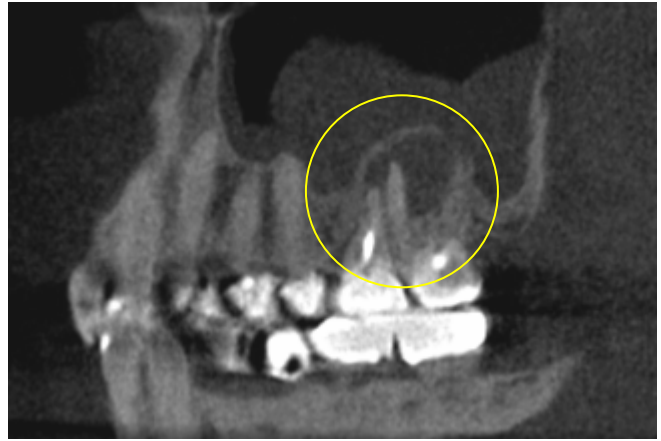
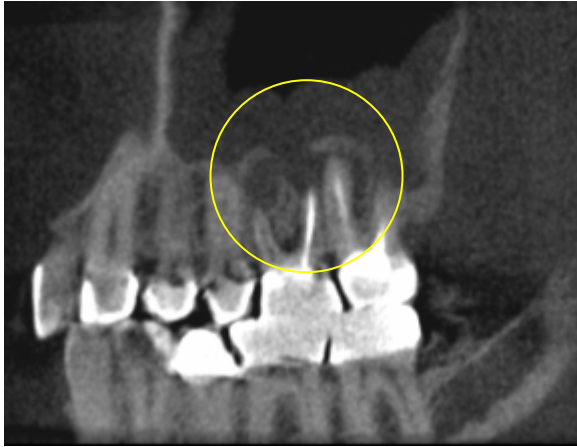Left TMJ



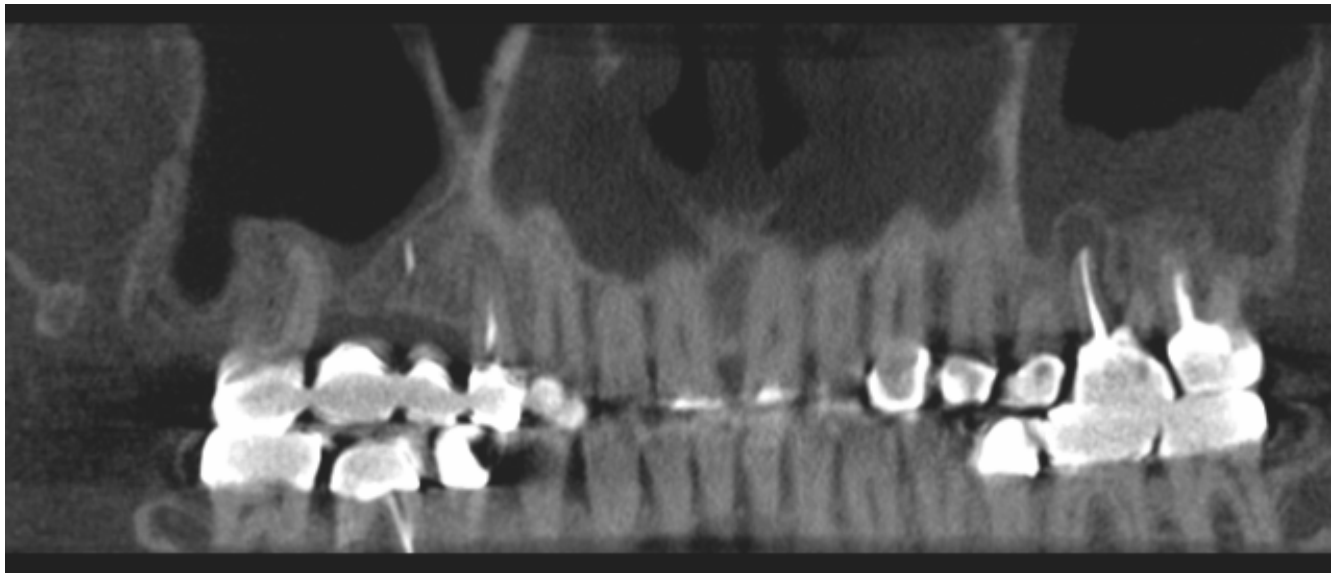
Maxilla superior to FPD at #3-4



Right maxilla



Left maxilla showing periapical cyst or granulomas at teeth #14 and 15



Reconstruct

ed panoramic