

Date:

Patient Name:
Center Name:
Referring Dentist:
Phone #:

DOB:

Gender:

Imaging Procedures: CT in the bone window: axial, coronal and sagittal views.

Clinical Info: Implants planned #1-3, 15, 19, 26-31

Findings:

The details for the implant sites can be seen in **Figures 1-3**.

Maxilla:

The labial aspect of the anterior maxillary arch is severely resorbed. There is a periapical radiolucency related to the root of endodontically treated #6. This may be a periapical scar if history of surgery is present, or it may be a periapical abscess, granuloma or cyst (**Fig. 4**)

Mandible:

Dense bone in the area of tooth # 31 (**Fig. 2 and 3e**).

TMJ:

Both condyles are positioned anteriorly in the fossae. The occlusion is faulty and a premature contact between the left molars is preventing complete interdigitation of the teeth and the correct positioning of the condyles in the fossae.

Right: anterior and posterior superior flattening of the head of the condyle with anterior osteophyte formation.

Left: anterior and posterior superior flattening of the head of the condyle.

Other findings:

- **Left carotid artery calcification (Fig 5).**
- Midline calcification in the brain consistent with pineal gland calcification (**Fig 6**).
- Nasal septum deviation to the left.

Recommendations:

Refer for ultrasonic evaluation to check extent of blockage of the carotid arteries.



Note: The measurements provided in this report are to give the dentist a general idea of the amount of bone remaining. It is recommended to perform exact measurements by the dentist during treatment planning.

Radiologist name and signature:

Dania Tamimi, BDS, DMSc, *Diplomate, ABOMR*

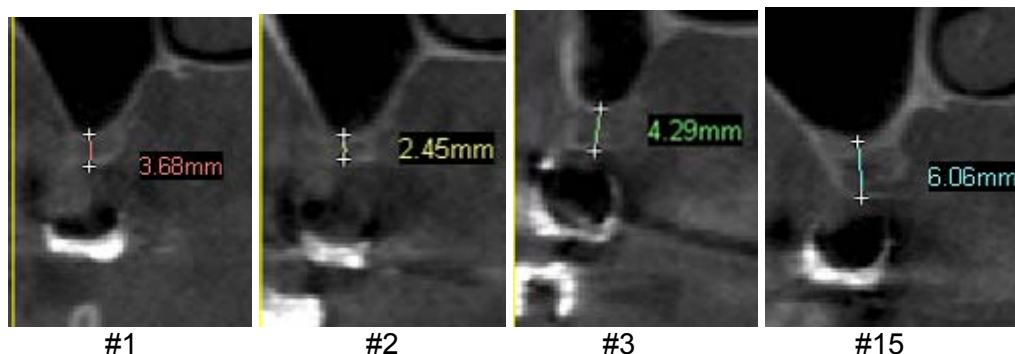


Figure 1: Maxillary implant sites. Note: The measurements in this report are to provide the dentist with a general idea of the condition of the alveolar bone. Accurate measurements should be performed by the dentist in the exact areas planned for implant placement.

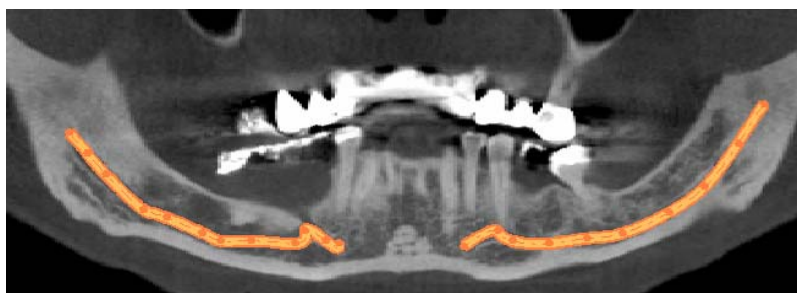


Figure 2: Location of the inferior alveolar nerve. Note the dense bone in the area of tooth #31, and the right mental foramen (appearing to emerge from the crest of the ridge because of the labial resorption and the orientation of the panoramic curve. This can be better visualized below in Fig 3 b.

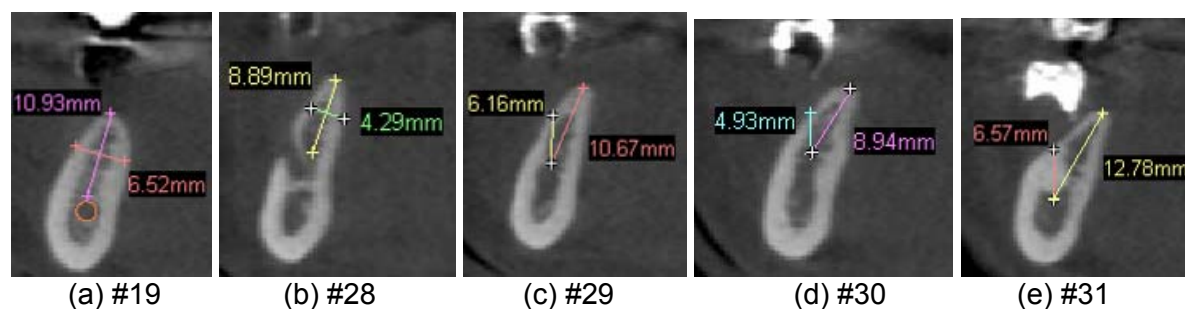


Figure 3: Mandibular implant sites

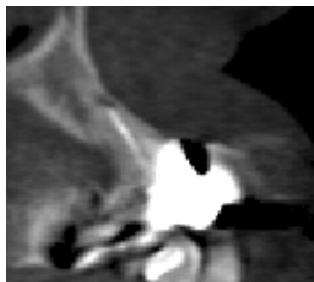


Figure 4: Periapical radiolucency related to tooth #6

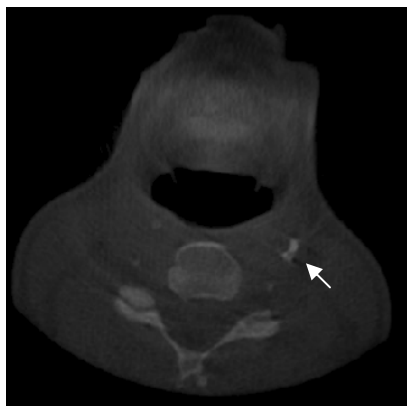

Figure 5: Left carotid calcification (arrow)

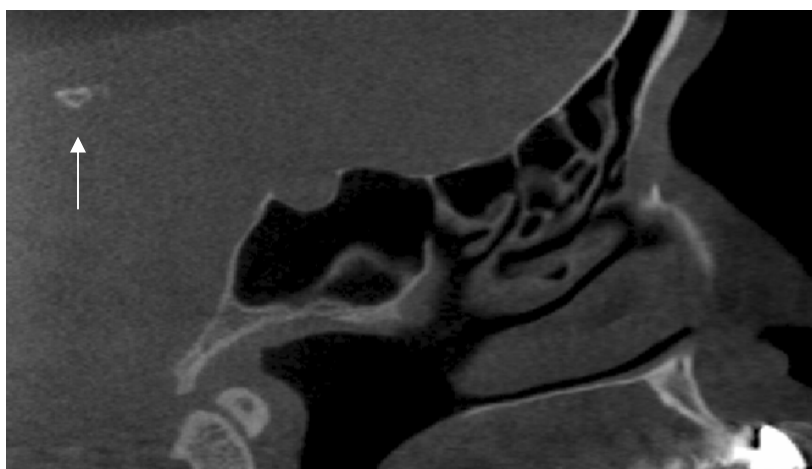


Figure 6: Midline calcification consistent with pineal gland calcification (arrow).